



A case of psoriasis-well treated with homoeopathy

Ashok Yadav, Nipun Singh Dabi, Sonu Mahiya, Priyanka Nagar

¹ Professor, HOD, Dept. of Practice of Medicine, Dr. M.P.K. Homoeopathic Medical College, Hospital and Research Centre, Homoeopathy University, Jaipur, Rajasthan, India

² MD Scholar, Dr. M.P.K Homoeopathic Medical College, Hospital and Research Centre, Homoeopathy University, Jaipur, Rajasthan, India

Abstract

Psoriasis is a non- infectious disease considered to be a chronic inflammatory autoimmune condition, t-cell mediated, in which faster replacement of epidermis cells on basal membrane level, causing inflammation and scaling. The more impact of this disease now a days on mental level and as a cosmetic purpose. Besides best conventional dermatological treatment homoeopathy play a major role in treatment of psoriasis without any side effect. Here we present a case of psoriasis well managed with homoeopathic remedy *Arsenic album*.

Case summary: A 55 years old male patient came with the complaint of eruptions over scalp and abdomen. Eruptions were dry with white crust and scaling. They were also present on abdomen. After considering the totality of the patient *Arsenicum album* 6CH was prescribed. The patient responded well with homoeopathy treatment and recovery occurred within 1 month. Hence, this case emphasizes the role of homoeopathy in the treatment of psoriasis.

Background: Psoriasis is one of the most common immune mediated dermatologic disease affecting upto 2% of world population.^[1] Its remitting and relapsing nature is a psychological and cosmetic problem for patients.

Keywords: plaque psoriasis, arsenicum album, homoeopathy, similimum

Introduction

Psoriasis is a most common chronic inflammatory dermatological condition characterized by well demarcated scaly plaque. It affects extensor surfaces, scalp and nails and has a relapsing and remitting course. It occurs in both sexes and at any age (uncommon under 5). It frequently affects the skin of the elbows, knees, scalp, lumbosacral areas, intergluteal cleft and glans penis. Typical lesion is well demarcated pink to salmon colored plaque covered by loosely adherent silver white scale. Nail changes occur in 30% of cases of psoriasis and consist of yellow brown discoloration with thimble pitting, onycholysis, thickening and crumbling.

Etiology

The exact cause is unknown but both genetic and environmental factors are important. Stress is a factor in susceptible individual while alcohol and smoking are also related.^[2] There is an association between metabolic syndrome and psoriasis.

The characteristic lesion is due to keratinocyte proliferation induced by secretion of cytokines and growth factors by T-cells. The stratum granulosum is thinned or absent and extensive overlying para-keratotic scale is seen. In susceptible individuals a local traumamay cause psoriatic lesion known as koebner phenomenon.^[2]

Types^[3]

- **Plaque psoriasis** is stable slow growing plaque which remains basically unchanged for long periods. Most common presentation is well raised demarcated erythematous plaque, located at extensor surfaces (elbow, knee), scalp, flexures. Untreated cases have silver/white scale, symmetrical involvement.

- **Guttate psoriasis** (eruptive psoriasis) present after a streptococcal throat infection most common in children and adolescents. Lesions are droplet shaped, small (<1cm), erythematous, scaly and numerous.
- **Pustular & Erythrodermic psoriasis** are the most severe types, reflecting widespread intense inflammation.

In 5-10%, individuals with psoriasis develop an inflammatory arthropathy more likely in patients with psoriatic nail disease.^[4]

Case Profile

A 55 year old male came with a complaint of eruptions over scalp and abdomen. Eruptions were dry with white crust and scaling.

History of presenting complaints and treatment history

Patient was apparently well 10 yrs back. Since then he suffered from scaling eruptions over head. He undertook various treatments which relieved the complaints for a period of time and again relapsed.

Personal history

He was a chronic smoker (13-14 bidi/day) for the past 20 years.

General symptoms

Patient is thermally chilly. All the complaints were aggravated during winter season. He was stressed and anxious about his disease on account of being suffering for a long time.

Physical examination

Patient was oriented with time, place and person. There were no signs of pallor, cyanosis, clubbing, icterus and lymphadenopathy. His blood pressure was 128/84 mm of Hg, pulse 78/min, afebrile, weight about 72 kg. He was tall and well built.

Provisional diagnosis

Plaque psoriasis

Totality of case

- Anxious for his disease
- General modality: aggravation cold
- Eruption scaly with white crust

- Erythematous eruption on abdomen

Repertorial analysis and result^[5]

1. *Calcarea carb* – 18/7
2. *Arsenic album* – 14/8
3. *Mercurius* – 11/8
4. *Sulphur* – 11/8
5. *Thuja occidentalis* – 8/8

Selection of remedy and potency

Arsenic album was selected on the basis of repertorial totality and comparison with different materia medica. 6CH potency was selected on the basis of susceptibility and age of the patient.

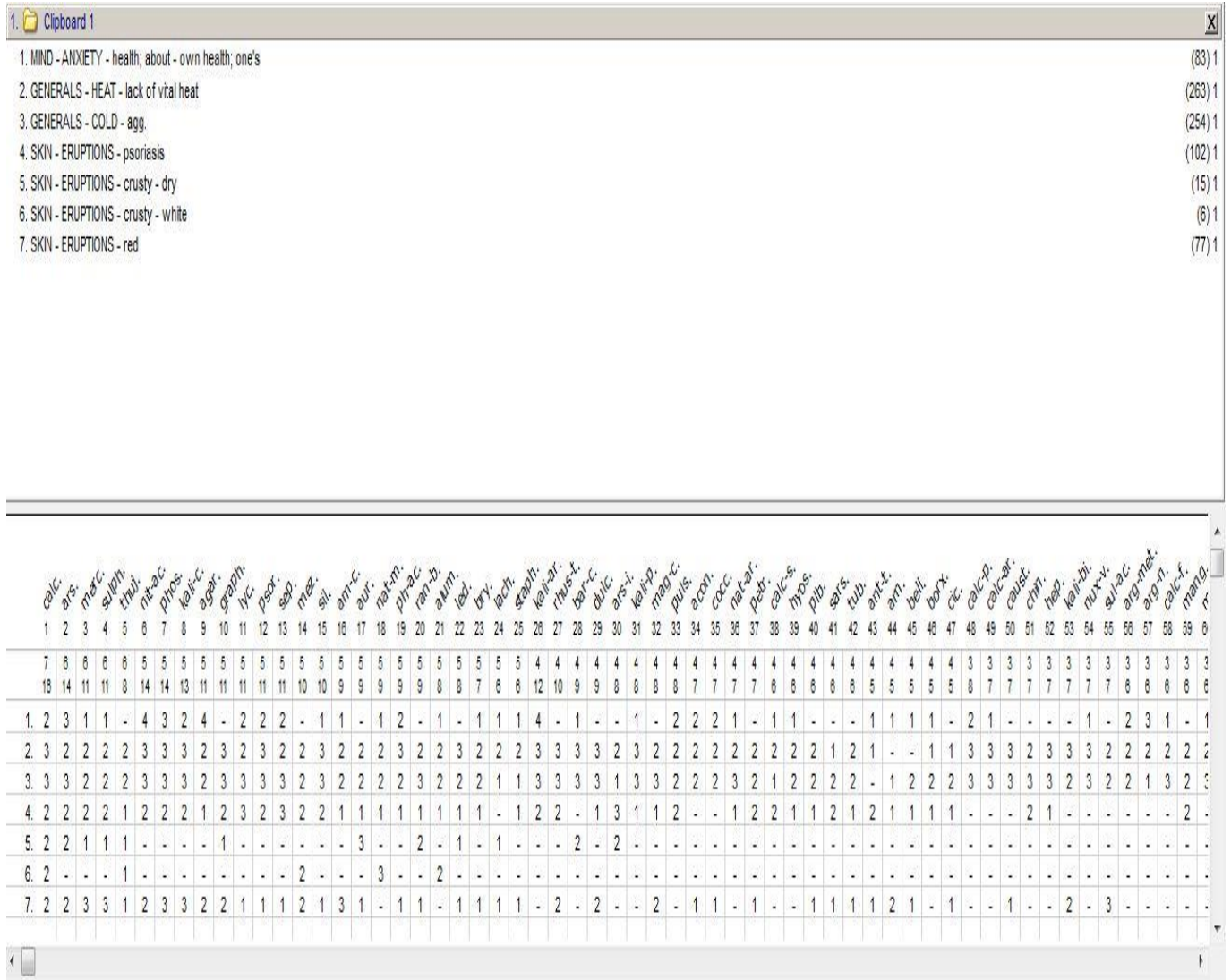


Fig 1

Table 1: Treatment and Follow-ups

Date	Symptoms	Prescription
14/12/2019	White scaly Eruption on scalp and well demarcated plaque on abdomen	Arsenicum album 6ch/1od for15days
02/01/2020	No any changes in complain, itching increase at night	Placebo 30/tds for 15 days
18/01/2020	Eruption are now less in size and area, no itching	Placebo 30/tds for 15 days
05/02/2020	No eruption on scalp with remission of erythematous scale	Rubrum 30/ tds for 15 dasy

Pre-treatment (14/12/2019)

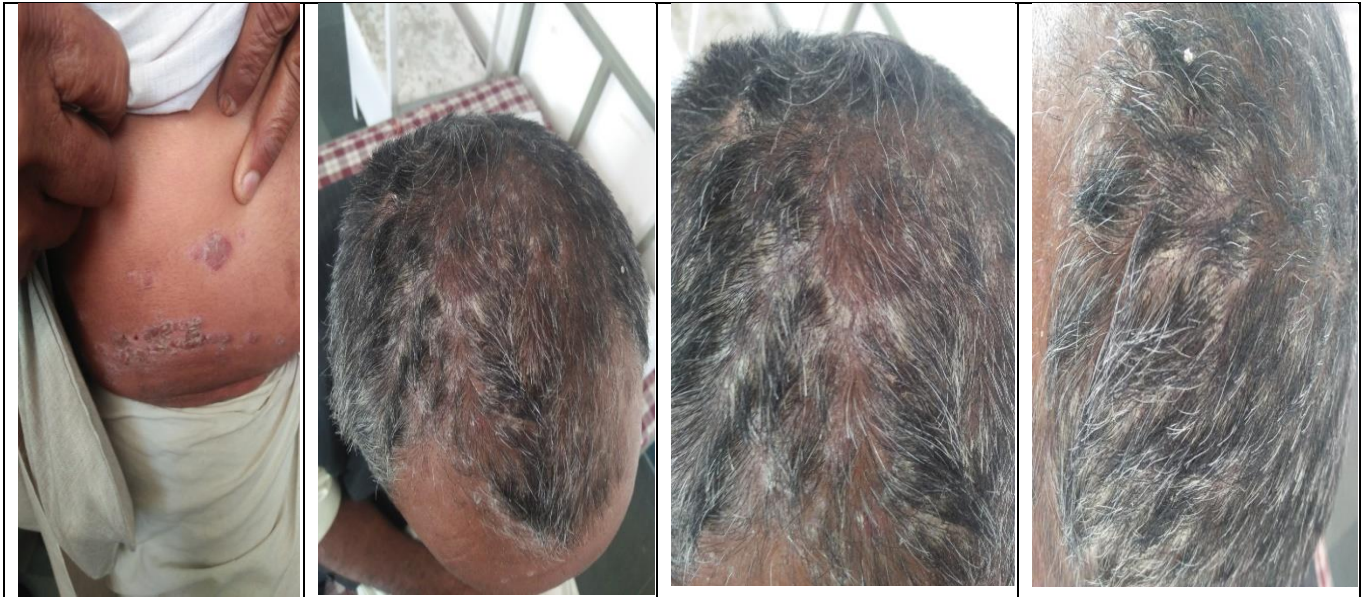

Fig 2

Post treatment (05/02/2020)

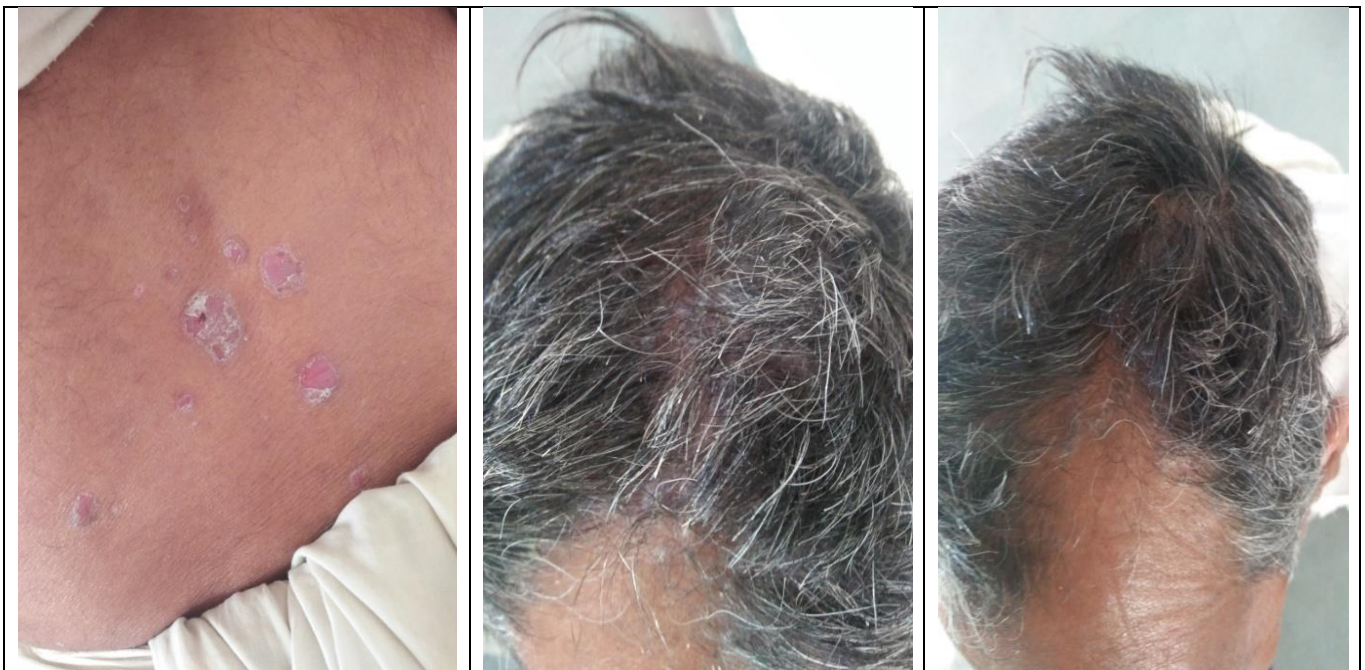

Fig 3

Conclusion and Result

Dermatological affections like psoriasis having a remitting and relapsing course leads to psychological stress for a patient and continuous treatment with topical glucocorticoids doesn't necessarily provide relief in cases associated with atrophy of skin and tachyphylaxis. The remedy selected on the basis of totality of characteristic symptoms and through individualization which covers the patient's mental, physical and particular symptoms, has the capability to cure the patient at the deeper level which leads to permanent restoration of health. The present case brings to light the effectiveness of Homoeopathy based on the principles of similimum in the treatment of psoriasis.

Declaration of Patient Consent

A written informed consent was taken from the patient. In the form, the patient has given written consent for his clinical information and images to be reported in the journal.

Financial Support and Sponsorship

Nil.

Conflicts of Interest

None declared.

References

1. Harrison T, Kasper D, Hauser S, Jameson J, Fauci A, Longo D et al. Harrison's principles of internal medicine.

- 20th ed. New York: McGraw-Hill Education; 2018.
2. Robbins S, Cotran R, Kumar V, Abbas A, Aster J. Pathologic Basis of Disease. 9th ed. Philadelphia, PA: Saunders Elsevier, 2015.
 3. Ralston S, Strachan M, Britton R, Penman I, Hobson R. Davidson's Principles & Practice Of Medicine. 23rd ed. Edinburgh: Elsevier, 2018.
 4. Kumar P, Clark M, Kumar, Clark's Clinical Medicine. 9th ed. Edinburgh: Elsevier, 1998.
 5. Schroyens F. Radar 10 Homoeopathic Repertory Software. CDROM. Available from: <http://www.archibel.com/radar10.html>.